

## LABYRINTHINE HYDROPS AS A CAUSE OF COCHLEO-VESTIBULAR PROBLEMS AFTER SCUBA DIVING: A "NEW" DIVING SYNDROME.

P. Vander Eecken<sup>1</sup>, P. Germonpré<sup>2</sup>

<sup>1</sup> ENT Dept., St. Lucas Hospital, Gent, Belgium, and <sup>2</sup> Centre for Hyperbaric Oxygen Therapy, Military Hospital 'Queen Astrid', Brussels, Belgium

### ABSTRACT

Labyrinthine Hydrops is until now - to our knowledge - an undescribed cause of vertigo and hearing problems after SCUBA diving. This "Ménière"-like syndrome occurs in divers who have moderate to severe middle ear equalisation problems, but is not associated with true inner ear barotrauma. Instead, the repeated oval window movements and perilymphatic changes of pressure induced by forceful Valsalva manoeuvres, probably induce a reactive rise in peri- and/or endolymphatic fluid production, causing a syndrome of acute vertigo, tinnitus and low-frequency hearing loss in the hours after surfacing.

The prognosis seems to be excellent, and eventually only classical anti-vertiginous drug therapy (type beta-histine) is indicated.

We present three case reports of divers who suffered from labyrinthine hydrops after SCUBA diving. The pathophysiology, symptoms and various differential diagnostic elements are discussed.

### INTRODUCTION

With the ever growing popularity of SCUBA diving, the rate of diving-related middle and inner ear injuries likewise has increased. Often, these injuries are related to a lack of knowledge or training. Climatic conditions may be responsible for the higher rate of these injuries in northern countries as opposed to those countries that possess more tropical diving waters.

Several divers presenting with a Ménière-like syndrome, occurring minutes to hours after surfacing, will be presented. Some of these had been treated in the past for inner ear decompression sickness (IEDS), presenting the same triad of symptoms: low frequency hearing loss, tinnitus and vertigo. These diving injuries occurred after relatively innocuous dives, and have been classified previously as "undeserved" IEDS. A common denominator in these episodes was a moderate Eustachian tube dysfunction, with usually an interruption during the descent due to ear equalisation problems. All symptoms cleared over a period of 5 to 6 days, and the course of disease seemed to be favourably influenced by a beta-histine treatment, as in Ménière's disease.

## SUBJECTS AND METHODS: CASE REPORTS

1. A female diver, 24 years old, makes a single dive to 15 msw for 35 minutes (bottom time 25 minutes) in a lake, at a water temperature of 5° Celsius. She has at the time a moderate viral rhinitis, and has not taken any medication before the dive. The dive is uneventful, except for an incomplete equalisation of the right ear, and a continuous feeling of pressure (no pain) during descent and bottom stay. A few minutes after surfacing, this pressure seems to increase, and she experiences a feeling of instability, unchanged by position changes (ie. supine position). There is a moderate nausea. Only 24 hours later, she is examined. Clinical examination is normal except for a slight congestion of the nasal mucosa. Micro-otoscopic examination shows no signs of middle ear barotrauma. Tympanometry is normal. Pure-tone audiometry reveals a sensorineural hearing loss of -20dB at frequencies 125, 250 and 500 Hz at the right side. Vestibular testing, including electronystagmography, is normal. She is in possession of an audiometry taken a few months before the accident, which was completely normal. She is treated with beta-histine 3x16mg daily. All symptoms disappear within 3 days. A control audiometry shows a complete hearing recovery.

The same patient presents 5 months later, 5 days after a similar episode of instability and sensation of fullness in the right ear, after an equally innocuous dive. She feels already much better at the time of the consultation, and pure-tone audiometry is normal. No therapy is given. She reports complete resolution of the symptoms only after 14 days of relative rest.

2. A healthy young male diver, 20 years old, makes a single dive to 17 msw, total dive time 40 minutes (bottom time 14 minutes), in the sea at a water temperature of 13° Celsius. The dive is uneventful, except for moderate pain in the right ear due to difficulties equalising. After the pain has cleared, the dive is continued with a slight feeling of pressure in the right ear (no pain). A few minutes after surfacing, a feeling of "sea-sickness" occurs, with nausea and a sensation of fullness in the right ear. Four hours after the onset of symptoms, he is examined. Clinical ENT examination reveals a retracted ear drum on the right side, without other signs of middle ear barotrauma. Tympanometry confirms a hypopressure in the right middle ear (-200 dapa, peak value 0.4ml vs. -85 dapa, peak value 0.6ml in the left ear). Pure tone audiometry shows a sensorineural hearing loss of -20 dB in the low frequencies only. Electronystagmography shows a hyperreactive right labyrinthine system (caloric tests). He is treated with beta-histine 3x16mg daily. All symptoms disappear within three days. Control audiometry shows full hearing recovery.
3. A healthy male diver of 48 years old, makes his second dive of the day. The first dive was 20 msw, 56 minutes total dive time (of which 15 minutes spent at depth), the surface interval was 4 hours. He now dives to 16 msw, makes multiple ascents-

descents between 16 msw and 5 msw, and surfaces after 25 minutes. The water temperature is 25° Celsius. Both during the first and the second dive there are some difficulties in equalising the middle ear pressure on the right side. Strainful Valsalva manoeuvres are used. There is moderate pain.

Twenty minutes after surfacing, he experiences rotational vertigo, and a sensation of fullness of the right ear. There is nausea but no vomiting.

He is examined some hours after the onset of these symptoms. Clinical examination reveals a Stage 1 barotrauma of the right ear drum. Tympanometry shows hypopressure in the right middle ear (-180 dapa, peak value 0.6ml vs. -30 dapa, peak value 0.8ml in the left ear). Pure tone audiometry shows a sensorineural hearing loss in the low frequency range to -20 dB. Electronystagmography is normal.

A treatment with oral decongestive drugs (an antihistaminic drug plus ephedrine) is started, with oral corticotherapy. The otoscopic examination returns to normal within 5 days, but the vertigo persists until the 10<sup>th</sup> day. The pure-tone audiometry shows a hearing recovery only after 3 weeks.

## DISCUSSION

Ménière's disease was first described by P. Ménière in 1861. It consists of periodic "attacks" of vertigo, tinnitus and low frequency hearing loss. It occurs preferentially in females in their forties, and is often triggered by stress, alcohol, caffeine use. The attacks last minutes to hours; there is complete recovery at first. With recurring episodes however, the low frequency hearing acuity is progressively destroyed.

The pathophysiology of Ménière's disease consists of a quantitative disturbance of the electrolyte concentration between endolymphatic and perilymphatic fluids, resulting in an osmotic pressure rise in the endolymphatic system (high potassium concentration). This pressure rise causes a rupture of Reissner's membrane, usually at the apex of the cochlea (helicotrema), seldom in the basal turns, in the sacculus or utriculus. Endolymphatic and perilymphatic fluids mix, and potassium penetrates in the intercellular space. The rise in potassium concentration provokes a depolarisation of the afferent neurones of the acoustic and vestibular nerve, and thus gives rise to the typical symptoms (Fig. 1).

The treatment consists in the restoration of ionic balance and volumes (acetazolamide, beta-histine), and anti-emetic drugs. In severe cases, a vestibular nerve section has been proposed. The efficacy of a translabyrinthine sacculotomy (in order to relieve the pressure in the endolymphatic sac and duct) is heavily disputed. Over years, there is a progressive decline in the hearing acuity. The vertigo is usually well controlled (central compensatory mechanisms).

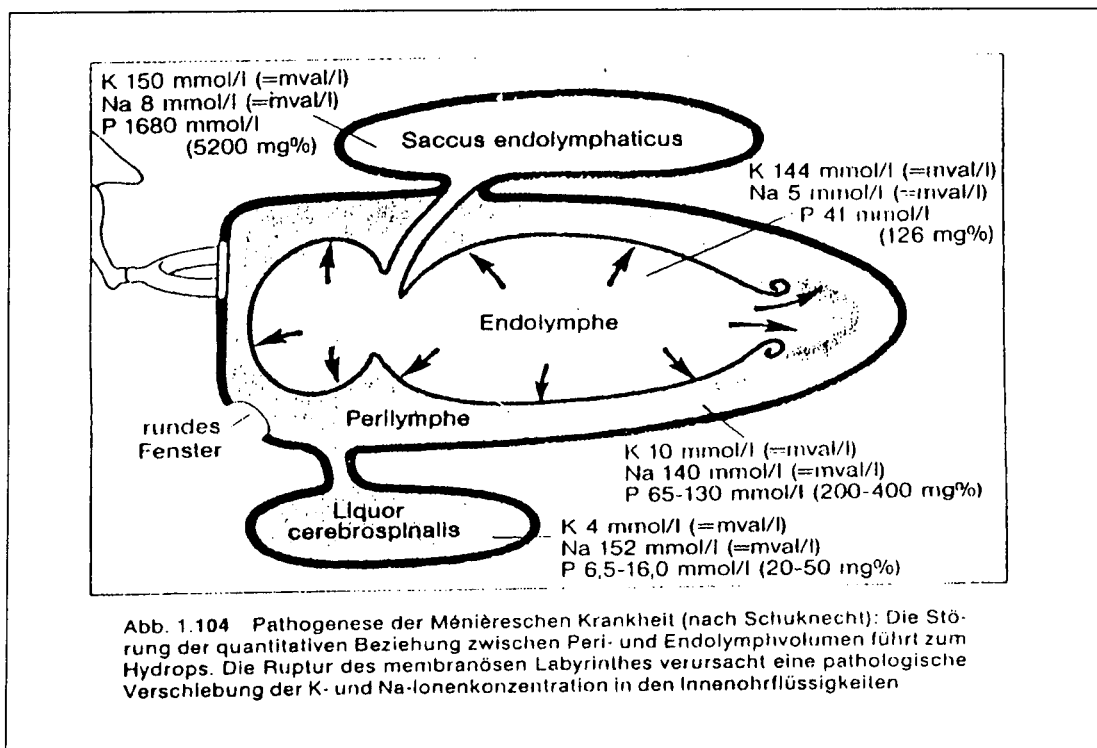


Figure 1: Pathogenesis of Ménière's disease (Becker *et al.*)

The divers we describe in this paper presented with Ménière-like symptoms: sudden onset of tinnitus, vertigo (rotational at first, with a remaining instability after a few hours) and low frequency hearing loss. These symptoms occurred a few minutes to a half hour after surfacing from the dive. All cases had experienced moderate Eustachian tube dysfunction during the dive, and reported moderate pain or sensation of fullness in one ear during the dive.

Inner ear decompression sickness (IEDS) was estimated to be unlikely in all cases, because of the shallow depth and/or short dive times. All cases were nevertheless investigated for patency of the Foramen Ovale (PFO), by means of trans-esophageal echocardiography. Cases 1 and 2 had no PFO, case 3 had a type 1 PFO (less than 20 bubbles).

Cerebellar decompression sickness (DCS) was also excluded, because of the dive profiles and the absence of other symptoms of DCS. None of the divers breathed oxygen as a first aid measure.

Inner ear barotrauma (IEB) was excluded because of the onset of symptoms only after the dive, and because of the very mild middle ear barotrauma. Also, hearing loss in IEB typically affects the high frequencies, because of a perilymphatic fistula or endo- or perilymphatic bleeding. IEB would however have to be suspected in case of persistent (3 to 5 days) rotational vertigo, even with normal otoscopic findings.

Finally, alternobaric vertigo should be considered. Although in two of the 3 cases, unequal middle ear pressures could be demonstrated, this diagnosis seems improbable because of the sensorineural hearing loss (no air-bone gap) and the persistence of symptoms over a period of days even with local or systemic nasal decongestive drugs.

We hypothesise that repeated high-amplitude tympanic movements (strained Valsalva manoeuvres) or a continuous pressure-induced inward protrusion of the tympanic membrane and thus, amplified by the ossicle chain, of the stapes footplate into the oval window, causes a pressure rise in the perilymph system. This perilymphatic hyperpressure would then cause a reactive hypersecretion of endolymphatic fluid. Upon surfacing, the perilymphatic pressure returns to normal, and a hydrops of the endolymphatic system will develop. Because of the delay between perilymphatic hyperpression and reactive endolymph secretion, a lag-time may exist in the appearance of the symptoms. A rupture of Reissner's membrane may occur, although it is possible that the symptoms are only due to an increased diffusion of potassium ions into the perilymph.

Treatment with beta-histine resulted in rapid resolution of symptoms in the first two patients, whereas no treatment or treatment with nasal decongestive drugs did not provide complete relief until after 2 to 3 weeks. As a precaution, beta-histine was continued for 2 to 3 weeks, and diving was suspended for 6 weeks. Further and more detailed (e.g. NMR) studies of future case reports will have to elucidate the exact pathogenesis and optimal treatment of this syndrome.

## CONCLUSION

Diving with rhinitis, sinusitis or Eustachian tube dysfunction is not recommended. However, most divers do not abort a dive or series of dives for moderate Eustachian tube problems. Strainful Valsalva manoeuvres are common practice for many divers, and will even be more common during cold water dives. Even if the ear can finally be "cleared", a mild middle ear hypopressure may persist during the dive.

A syndrome of vertigo, tinnitus and hearing loss, after a dive, often presents a difficult diagnostic problem. Inner ear decompression sickness and inner ear barotrauma require quite different treatment regimens, with a quite different degree of urgency.

We presented three case reports of a "new" syndrome, with an excellent prognosis (at least on the short term), and a effective treatment. Over the past few months, three more cases were diagnosed, one of which had in the past undergone repeated hyperbaric treatment for suspected decompression sickness. Careful analysis of the accidental dive, the symptoms and their time course might have diagnosed this case earlier.

We propose to add "endolymphatic hydrops" to the list of differential diagnoses of acute vertigo and hearing loss after a SCUBA dive.

## REFERENCES

1. Becker, W., H.H.Nauman, and C.R. Pfaltz (1990). Hals-Nasen-Ohren-Heilkunde.
2. Farmer, J.C. (1982). Otologic and paranasal problems in diving. In: *The Physiology and Medicine of Diving*. P.B. Bennett and D.H. Elliot (Eds.). Best Publishing Co., San Pedro, CA, pp. 507-536.
3. Shupak, A., I. Doweck, E. Greenberg, C.R.Gordon, O. Spitzer, Y. Melamed and W.S. Meyer (1991). Diving-related inner ear injuries. *Laryngoscope* 101: 173-179.
4. Simmons, F.B. (1979). The double-membrane break syndrome in sudden hearing loss. *Laryngoscope* 89: 59-66.

Dr. Paul VANDER EECKEN  
Neus - Keel - Oorheekunde  
A.Z. Sint-Vincentius Gent  
Tel. 09/235 74 01 1-4351248-410

